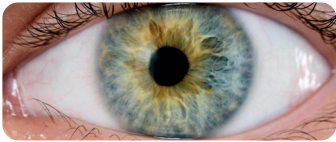
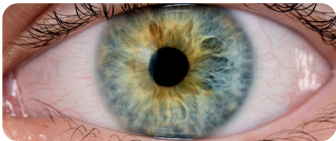

The *ECOS-G UK Scale* of ocular hyperaemia for glaucoma and dry eye



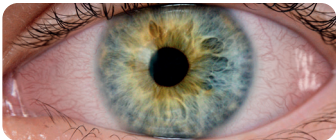
- Normal

No injection present



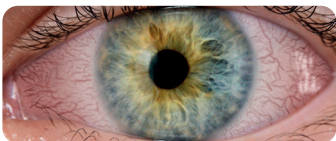+ Trace

Slight limbal (mild segmented) and/or bulbar (mild regional) injection present



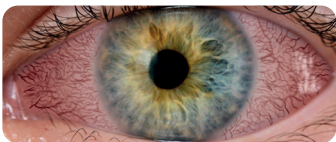
++ Mild

Mild limbal (mild circumcorneal) and/or bulbar (mild diffuse) injection present



+++ Moderate

Significant limbal (marked segmented) and/or bulbar (marked regional or diffuse) injection present



++++ Severe

Severe limbal (marked circumcorneal) and/or bulbar (diffuse episcleral or scleral) injection present

Educational Club of Ocular Surface & Glaucoma UK Consensus 2023